

# EFFICACY OF SUTURE VERSUS SUTURELESS TECHNIQUE AFTER PERIODONTAL FLAP SURGERY – A SPLIT MOUTH STUDY

Suturing is an integral part of periodontal flap surgery, but it has disadvantages such as difficulty in maintaining oral hygiene, increased post-operative discomfort, and higher infection rate. To overcome these problems, a search for alternative methods like tissue adhesives, which is a sutureless technique has been used.

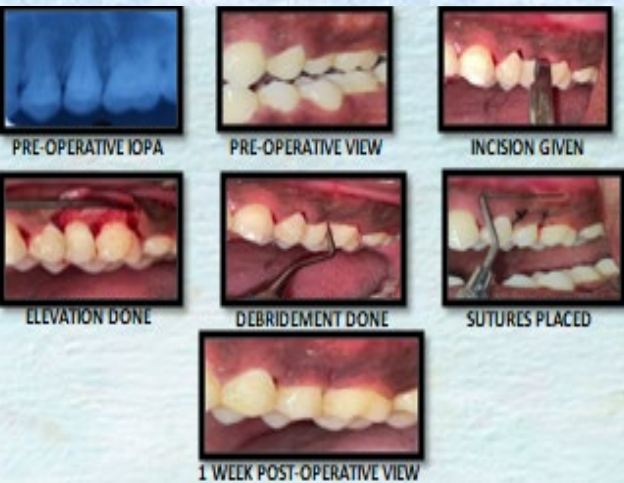## OBJECTIVE OF THE STUDY

To compare the stability & healing properties after periodontal flap surgery using tissue adhesive and surgical sutures.

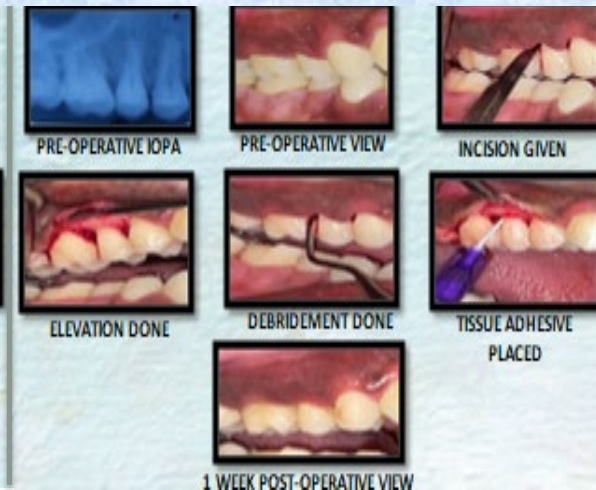## MATERIALS & METHODS

- Bilateral split mouth study
- Sample size : 10 quadrants in 5 patients
- **Control group** : Suture group
- **Test group** : Sutureless - Tissue adhesive (TRUSEAL) group
- Parameters assessed : Plaque index, Roll test, Visual Analog Scale and Wound Healing Index – immediately after surgery and 7 days post-operatively.
- Periodontal flap surgery was done on five patients bilaterally, followed by stabilisation and approximation of surgical site using 4-0 silk suture on one side (Control Group) and tissue adhesive on other side (Test Group).

### TEST GROUP



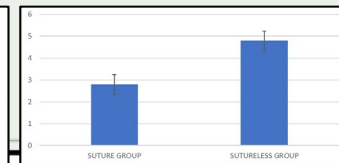
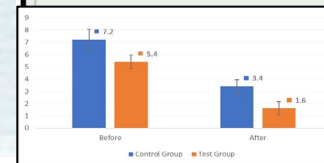
### CONTROL GROUP



## RESULT

With respect to *Laundry et al., 1988* scoring index for Wound healing. The mean value of control group is  $4.8 \pm 0.4$  and Test group mean value is  $2.8 \pm 0.44$  which is statistically significant.

When comparing both the groups, statistical difference was seen in terms of Visual analogue score measure immediately after surgery and 7 days postoperatively.



## DISCUSSION

*Dipika et al., (2020)* reported that cyanoacrylate group showed significant improvement in Plaque index, Colony forming units, C-reactive protein levels and VAS score for discomfort, aesthetics and ease maintenance.

*Chandro et al., (2023)* concluded that N-Butyl cyanoacrylate is a reliable alternative to conventional sutures as it is easy to apply, shortens the operation time, causes a less inflammatory response, and reduces postoperative pain while facilitating primary closure similar to conventional silk sutures.




## CONCLUSION

Cyanoacrylate tissue adhesive is clinically effective in the stabilization of the flap and has excellent wound healing and can be used as an alternative to sutures.



ROSEMAN UNIVERSITY  
OF HEALTH SCIENCES

TRANSFORMING EDUCATION    REIMAGINING HEALTHCARE    EMBRACING DISCOVERY    COMMITTED TO COMMUNITY




ROSEMAN UNIVERSITY  
OF HEALTH SCIENCES

TRANSFORMING  
EDUCATION

REIMAGINING  
HEALTHCARE


EMBRACING  
DISCOVERY

COMMITTED TO  
COMMUNITY



ROSEMAN UNIVERSITY  
OF HEALTH SCIENCES

TRANSFORMING EDUCATION    REIMAGINING HEALTHCARE    EMBRACING DISCOVERY    COMMITTED TO COMMUNITY





**ROSEMAN UNIVERSITY**  
OF HEALTH SCIENCES

TRANSFORMING EDUCATION    REIMAGINING HEALTHCARE    EMBRACING DISCOVERY    COMMITTED TO COMMUNITY

